



SPECIAL FEATURE

Disc Surgery in Motion

Rudolph Bertagnoli, MD
Spinecenter, St. Elizabeth Klinikum
Straubing, Germany

The following article is adapted from the keynote address, "Raison d'etre for Spine Arthroplasty," presented by Dr. Rudolph Bertagnoli at NASS' 19th Annual Meeting in Chicago, October 26-30, 2004.

Impaired musculoskeletal conditions are the most frequent cause of disability worldwide and the number one reason for doctor visits in the US. Spine surgery is among the top three reasons for hospitalization in the US and Europe.

INTRODUCTION

Back pain is the most widespread disease worldwide. Approximately 40% of the population aged 25 to 74 years is affected. Impaired musculoskeletal conditions are the most frequent cause of disability worldwide and the number one reason for doctor visits in the US. Spine surgery is among the top three reasons for hospitalization in the US and Europe. Every fifth sick certificate is issued because of chronic back pain, which is also the number one cause of employee absenteeism in the US.

The need for treatment is still increasing because the number of patients with musculoskeletal diseases and back pain is on the rise. The principal reasons for this can be found in age and lifestyle changes. The lifestyle has changed to more sedentary work and more unhealthy factors that promote degenerative disc diseases (DDD). The increasing number of patients results in a higher number of operations performed to treat lumbar degenerative disc disease in the industrialized nations. This is leading to an increase in absolute terms in the number of patients with problems that arise in connection with unfavourable surgical results.¹ Intersgmental instability following nucleotomy and after fusion surgery are two of the major problems encountered in this context. Long-term results have improved somewhat in part because of the development of increasingly sophisticated surgical techniques and because of the invention of numerous elegant surgical implants for use in conjunction with intervertebral disc and fusion surgery.² Also, the successful fusion rate has improved. This rate increase has been especially noticeable in association with the development of interbody disc cages.³⁻⁷ Nevertheless the incidence of failure is still sufficiently high to warrant a critical analysis of the indications, surgical techniques and implantable appliances applicable to this complex field of diagnosis and therapy.²

SURGICAL TREATMENT STRATEGIES

Looking at the classic decompressive-type and fusion-type surgeries, there are currently three main strategies for the surgical treatment of DDD: percutaneous decompression techniques, open (eg, microsurgical) and fusion techniques (with or without instrumentation and associated discectomy).²

The first two strategies are decompressive surgical techniques but they also carry with them an inherent spinal destabilizing effect. The main objectives of these techniques are the direct or indirect decompression of neural structures (eg, spinal nerves or spinal cord). Iatrogenic spinal instability as well as collateral damage of surrounding tissue can usually be reduced to a minimum using minimal invasive strategies.

Compared with open nucleotomy, the percutaneous endoscopic methods have various inherent technical problems and usually require a larger number of surgical instruments and training; in general, they have less favourable results and thus have not successfully replaced the open microsurgical techniques.² The range of indications for the former is considerably more narrow than that for the open techniques, and essentially includes small- to medium-sized, nonsequestered disc herniations.



Open surgery methods are characterized by achieving a greater degree of spinal decompression, but the approach causes considerably more unavoidable surgically induced trauma and therefore also more collateral damage to surrounding tissue. As a consequence, the destabilizing effects upon the linked motion segments are typically much greater than those observed in the percutaneous techniques. Overall, a total of 3% to 14% of all patients undergoing simple disc surgery has to be operated again because of persistent or recurrent complaints.^{8,9}

Intersegmental fusion techniques (with or without neural decompression/discectomy) have been focused on the development of new implants, advanced surgical methods and biological inducement (eg, bone morphogenetic proteins) in recent years. Even though fusion is the standard surgery for patients with instability as a major component and for cases with no alternative treatment available, the clinical success rate ranges only from 50% to 75% (compared to the radiographic fusion success rate from 85% to 95%). The relatively low clinical success rate which doesn't correlate with the relatively high fusion rate might be based on the disadvantages that fusion has, eg, no restoration of the natural disc function because of obliteration of anatomy and elimination of movement by the fusion procedure with increased stiffness and missing capability of flexion. This may increase the potential for long-term complications ("fusion diseases" such as facet hypertrophy, facet arthritis, spinal stenosis, osteophyte formation, posterior muscular debilitation and adjacent-level disc degeneration).

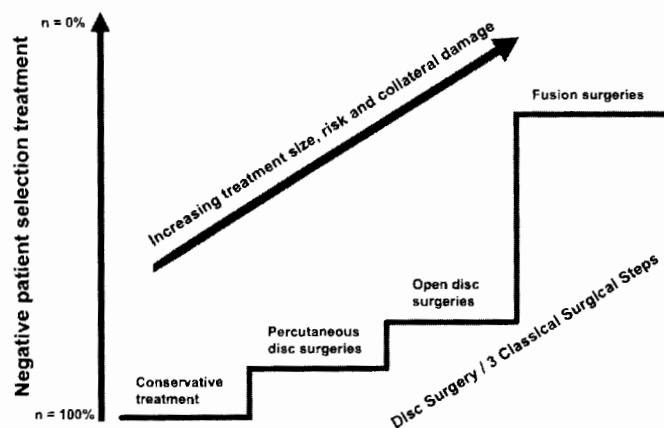
With the existing treatment strategies we cannot generate a 100% success rate. Therefore we are looking at a treatment algorithm where we do not apply the maximum possible but the most adequate treatment for the specific condition. This compromise is based on a "treatment of little and increasing invasive therapy steps." To achieve a better success rate, the therapy should ideally consist of a reasoned series of small treatment steps with the aim of minimising the absolute number of patients ultimately operated upon by means of 'negative patient selection' (ie, using exclusion

criteria to direct patients towards an alternate form of therapy, only focusing on "non-responders" in each category). This is especially important, as the interventions become increasingly major in degree of risks and collateral damage.² This 'Step Algorithm' can be introduced in the treatment of DDD as a very individualized treatment with optimal performance (**Figure 1**)

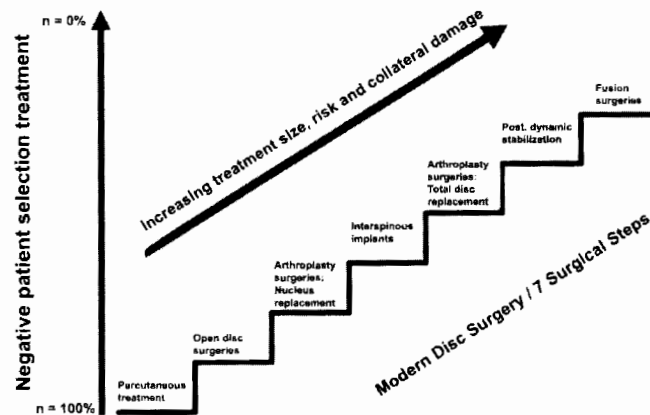
The more we proceed to the higher steps, the larger becomes the treatment size combined with higher risk factors and larger collateral damage to surrounding structures. Presently, the first treatment step is the conservative therapy followed by the three classical surgical steps: (1) percutaneous disc surgeries, (2) open disc surgeries and (3) fusion surgery. The treatment of the small therapy steps means that the collateral trauma caused by surgery can be minimized along this pathway, and if one therapy concept fails, a further treatment step in this reasoned stepwise sequence can be offered to the patient. Currently, there is a large gap between the decompressive treatment (percutaneous or open decompressive techniques) and fusion surgical techniques.

Because of the improvement in non-fusion technologies in the future, the modern treatment algorithm of DDD will include seven surgical steps: (1) percutaneous decompression techniques, (2) open decompression techniques, (3) nucleus replacement, eg, PDN (Raymedica), Neudisc (Replication Medical), DASCOR (Disc Dynamics), (4) interspinous implants, eg, Wallis (Spine Next), Interspinous U (Fixano), DIAM (Medtronic), (5) total disc replacement, eg, Charité (Johnson & Johnson DePuy Acromed), Prodisc (Synthes), Maverick (Medtronic Sofamor Danck), Flexicore (SpineCore), (6) posterior dynamic dorsal stabilization, eg, Dynesys (Zimmer) and (7) fusion surgeries. Nevertheless, conservative treatment should always be the first step before surgery.

Currently about 60 nonfusion products and technologies are under development. These technologies will allow the spine to stabilize towards its natural biomechanical state. It will help rebalance the spinal segment and restore the natural anatomical function of the spine. Nonfusion implants have the goal of sparing



IA



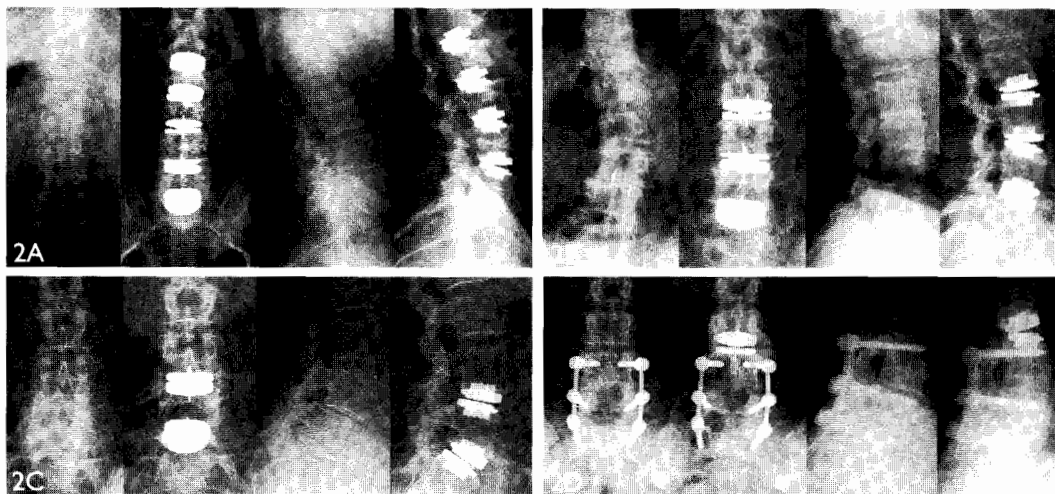
IB

Figure 1. Step algorithms: IA, classical surgical steps and IB, modern disc surgery.



Figure 2. Expanded indications:

- 2A: Total disc replacement (Prodisc), multilevel case.
- 2B: Total disc replacement (Prodisc), degenerative scoliosis case.
- 2C: Total disc replacement (Prodisc), degenerative spondylolisthesis case.
- 2D: Total disc replacement (Prodisc), adjacent to fusion case.



tissue and will have almost no negative influence for an eventually necessary more invasive procedure in the future. Total disc replacement (TDR), which requires an anterior surgical approach and the removal of the entire disc, is expected to replace most of the fusion procedures in DDD. This assumption is based on clinical outcomes at least as good as with fusion techniques, eg, less invasion, reduction in adjacent level degeneration, faster recovery and the possibility of a final fusion procedure. Expanded indications for the use of TDR are multilevel degeneration (> 2 levels), residual intersegmental instability following a fusion surgery, degenerative scoliosis and mobile degenerative spondylolisthesis (grade I and II), all of which are in clinical evaluation as prospective studies (Figure 2).

Although we think that motion preserving surgery will be the way to treat DDD patients in the near future, fusion surgeries will still remain in the spine surgeon's portfolio as an important treatment option. The domain for these procedures will be the "real" spinal problems and instabilities, like fractures, tumors, severe deformations, spondylodiscitis, or very late stage DDD.

DISC ARTHROPLASTY

Disc arthroplasty began to be considered at the beginning of the 1950s in an attempt to achieve the major goals of maintaining mobility of the intervertebral motion segment and restoring natural disc function.¹⁰ The first artificial disc, patented in 1956 in France, may never have been implanted. First progress in clinical use was achieved by Fernström in 1966. He implanted a stainless steel ball bearing into the disc space after discectomy and thereby segmental hypermobility and the tendency to subside into vertebral end plates were created. The Fernström ball was implanted in approximately 250 patients. In the 1970s, a new concept with the goal to achieve mobility through articulation between the concave and convex surfaces of a multicomponent device came into existence. Even though some of these implants have been patented, they

were not successful because of failures (eg, poor durability, toxicity, migration).

Since the beginning of implant development, more than 70 different materials and devices have evolved: from preformed implants with various attachment schemes to injectable plastics that undergo polymerization in situ. But only very few methods have ultimately entered into clinical trials.

Treatment goals, contraindications, indications. The most important goals of disc replacement surgery are to maintain or restore intersegmental mobility, restore the disc height and the spine balance and to avoid damage of adjacent segments while removing the nucleus or the entire disc. By restoring the original disc height, two other potential generators of pain in the intervertebral motion segment—the posterior spinal facet (ie, zygapophyseal) joints and the nerve roots—can be indirectly addressed.² The increase in disc space height leads to neural foramen enlargement and, hence, to decompression of the existing neural structures within the foramen.⁷ In addition, a reduction of stress on the posterior facets is also achieved with disc height re-expansion, thus relieving facet compression pain.

The use of disc prostheses is contraindicated in patients with advanced osteoporosis or other major underlying bony pathology (ie, metastatic or infectious disease) having inherently reduced load-bearing capacities of the vertebral bodies and end plates. Dominantly posterior spinal pathologies such as lytic spondylolisthesis, severe nondiscal central or severe lateral spinal canal stenosis associated with hypertrophic posterior spinal facet joints, postoperative absence of the posterior spinal elements following laminectomy and facetectomy, acute spinal fractures, tumours, spondylodiscitis and ventral approach related problems are also contraindications.² However, in any surgical procedure, proper adherence to the indications is vital in order to achieve successful postoperative results. As good rule, all conservative treatment options should be exhausted before a surgery is undertaken.



Disc arthroplasty techniques. In the area of intervertebral disc replacement with an artificial disc, basically either the nucleus pulposus or the entire intervertebral disc can be replaced. In nucleus replacement, a native implant ‘container’ that is mechanically stable has to be present. Adequate stability of the patient’s peripheral annulus fibrosus is therefore a basic requisite for successful nucleus replacement surgery. Therefore, candidates for nucleus replacement should not have extreme intersegmental degeneration.¹¹⁻¹⁴

The prosthesis in the case of total disc prostheses, in contrast to isolated nucleus pulposus replacement, is attached directly to the bone of the adjacent vertebral bodies. Therefore, this type of prosthesis does not require the annulus fibrosus to function as a container for the implant and for this reason the implants essentially do not depend so much on intact native biomechanical disc factors. Therefore, intersegmental degeneration may be considerably more advanced in such cases.²

The indications for one or the other of this group of implants thus differ primarily in terms of the degree of intersegmental degeneration that exists before surgery.¹⁵⁻¹⁸

NUCLEUS REPLACEMENT SURGERY /PARTIAL DISC PROSTHESES

Replacing the pathologically altered nuclear material in order to halt the delamination process in the annulus fibrosus caused by the hypermobile instability is the first goal of nucleus replacement implants. Partial disc prostheses are also designed to prevent further progression of vertical instability caused by a loss of intervertebral disc space height and the negative sequelae this entails.⁷

The primary symptom for a nucleus replacement disc should be relevant lumbar pain, ie, low back pain with or without radicular pain. The ideal indication for partial artificial nucleus replacement is single level degenerative disc with a large disc height.⁷ Reliable results for other potential indications, such as postnucleotomy syndrome or primary nonsequestered disc herniation, are still under investigation and therefore, nucleus prostheses for these indications cannot be recommended at present.

At present, only the prosthetic disc nucleus (PDN) is in a larger clinical trial (**Figure 3A**). Charles Ray developed the PDN (Raymedica) in the 1980s. The original PDN, a two-pillow hydrogel (compared to the single-pillow design at the present), was completed in 1995 and first implanted in 1996. It consists of a dehydrated, compressed polymer hydrogel that is osmotically active.

Initially, the PDN was developed for a posterior surgical approach in which the posterior annulus is weakened by the incision of the annulus fibrosus to allow the insertion of the PDN which causes decreased resistance to implant migration. To prevent the migration into the central spinal canal that occurs in up to 8% of cases using the posterior approach, we developed a new ventral insertion technique by using an anterolateral transpsoatic muscle approach (ALPA).¹⁹ The annulus fibrosus is surgically weakened in the lateral part of the disc, which does not affect the important

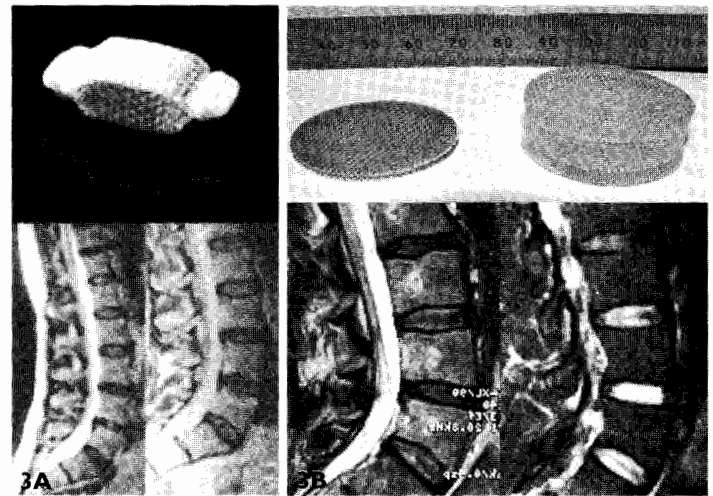


Figure 3. Nucleus Replacement. 3A top: PDN-solo device. 3A bottom: MRI PDN-Dual. 3B, top: Neudisc device. 3B bottom: MRI Neudisc case.

retaining tension bands (eg, anterior or posterior longitudinal ligament: ALL/PLL). In addition, the weak point is no longer in the direction of flexion or extension, the major direction of potential migration of lumbar disc prosthesis implants. Up to now, there have been no cases of migration of PDN implants inserted using the ALPA approach.² The latest version, the ‘‘PDN-solo,’’ solves a lot of the former problems that have been detected with the dual implants.

Recently, other implants like the Neudisc (**Figure 3B**) or DASCOR have started human application with promising early results.

TOTAL DISC REPLACEMENT

This technology offers a treatment alternative for patients with later-stage degenerative disc disease. Total disc prostheses can be used for single^{20,21} or bilevel²² lumbar discopathy or intersegmental hypermobile instability without significant posterior changes (ie, no major degenerative or postoperative alterations of spinous process, laminae and posterior facet joints). They can also be used in patients with single or bilevel postdiscectomy syndrome or failed back surgery syndrome. The devices are implanted with the intention of being biomechanically independent of disc tissue. The goal of the surgery is to completely replace the disc as the pain generator using a mechanical device to re-establish anatomy (intervertebral disc space height), to restore the segment mobility to a state of normal or near normal, to minimize stress on adjacent segments and to protect neural structure. The larger size of the implants covers almost the entire adjacent vertebral end plate surfaces,²³ so that the types of prostheses can only be inserted ventrally using a retro- or transperitoneal approach.

SB Charit  prosthesis. The Charit  prosthesis that was created by Schellnack and B ttner-Janz was the first design to be adopted

clinically. This prosthesis is now in its third generation of development and the most widely used complete disc replacement implant at present. The first implantation was in 1984. This prosthesis was approved in the US by the FDA in November 2004.

Compared with the other disc prostheses presently available on the market (eg, ProDisc L, Maverick and Flexicore), the SB Charité prosthesis has the most ‘unconstrained’ kinematic characteristics. The prosthesis consists of a biconvex polyethylene core that lies between two cobalt-chromium-molybdenum alloy (CrCoMo) end plates which are coated with hydroxyapatite to enhance osseointegration (nonUS version) or uncoated (US version). Because of the biconvex shape of the polyethylene core, the intervertebral disc space has to be distracted to a greater degree in order not to damage the polyethylene part.²

ProDisc L. In the late 1980s, Thierry Marnay designed a semiconstrained total disc device, the ProDisc. In the second generation (ProDisc L), the ProDisc has been improved in sense of design and application technique.

The prosthesis consists of two end plates made of a CrCoMo alloy coated with a Titanium Plasmapore surface to improve osseointegration. In contrast to the SB Charité prosthesis, a monoconvex polyethylene core that forms a ball and socket is used in the ProDisc L prosthesis.² By using a multifunctional instrument, the core is inserted into the caudal end plate of the implant. The ProDisc L can be positioned easily with a high precision even if space is limited because of the anatomic conditions or if the course of the vasculature is unfavourable.²

Maverick. The Maverick (Medtronic Sofamor Danek) is a semiconstrained two piece metal-on-metal device. The end plates have—like the ProDisc—a midline keel and surface coating for bone ingrowth. The Maverick prosthesis was introduced in late 2001 and has been in investigational device exemption (IDE) clinical trials since 2003.

Flexicore. The Flexicore (SpineCore) prosthesis was developed and designed by Thomas Errico. It is a constrained metal-on-metal device. The end plates have small pegs for fixation into the vertebral bone and surface coating for bone ingrowth into the metal. The Flexicore is in an IDE clinical trial as well.

POSTERIOR DYNAMIC STABILIZATION

Posterior dynamic stabilization technologies have been in clinical studies since the 1980s. One of the first technologies was the “Graf ligament” developed in the late 1980s/early 1990s by Henri Graf. This pedicle-screw based system connected by flexible polyester bands strung between vertebrae. The long term results of the Graf ligament have not been so favourable because the device could not be preloaded and relied on a constant anatomical height of the disc. The surgery often showed poor clinical results caused by cord breakage, cutting of bone by metal wire and inability to achieve dynamic stability. The main difference to disc arthroplasty is re-

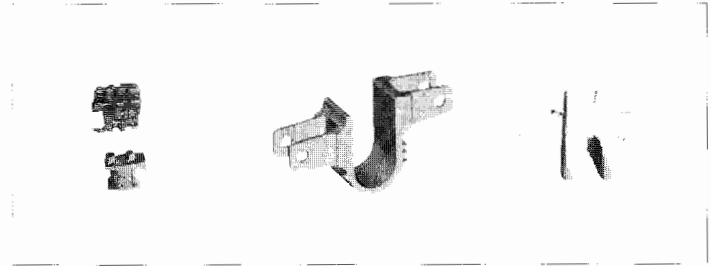


Figure 4. Interspinous Devices. Left: Wallis Device. Center: Fixano Interspinous U Device. Right: DIAM Device.

duced mobility, maintaining the flexibility of the area and the posterior application.

Current posterior dynamic stabilization technologies fall into two main categories: interspinous spacers and the pedicle-screw based systems.

■ **Interspinous spacers**, such as DIAM (Medtronic), Wallis (Spine Next) and Interspinous U (Fixano) (**Figure 4**) are less invasive concepts and are expected to be used for patients with mainly posterior element disease and with early-stage disc disease. Posterior access, minimal anatomical destruction, the ability to offer additional stabilization to nucleus replacement or TDR are some potential benefits of interspinous process spacer systems. In 1986, Jacques S en egas, MD, began to implant a first generation version of the Spine Next Wallis, a titanium interspinous spacer combined with the previous concept of a cord consisting of woven polyester.

■ **Pedicle screw-based systems**, eg, Dynesys, will be used among other indications to treat patients with degenerative spondylolisthesis, laminectomies and stenosis. At present, the Dynesys system, implanted since the mid to late 1990s, is the world’s leading pedicle screw-based dynamic stabilization system. In the Dynesys system, a polyurethane cylinder has been added to maintain the heads of the pedicular screws in a constant distance. Together with the ligament a flexible system can be generated. The indication for this device is DDD in which reduction of motion is the target. It also can be used in an earlier degenerative situation because in some cases a rehydration of the disc has been observed. Like in all pedicle screw systems, bone quality and screw position is a critical issue because loosening of screws has been observed to be the biggest long-term problem.

CONCLUSION

Motion preserving techniques will offer the opportunity to achieve intersegmental stabilization coupled with retained intersegmental mobility, a goal that was unattainable in the past. Degenerative spinal disorders may radically change by using artificial discs or posterior dynamic devices. Although the current clinical studies show good results, it is important to critically judge the numerous different developments that are expected to appear under strict prospective study conditions. Implants that are already undergo-



ing clinical trials still have to demonstrate whether the good short-term results can be maintained in the medium- and long-term. Individual indications for the various techniques must be defined and differentiated to enable an optimal, tailor-made treatment to be selected for each patient from the growing repertoire that spine surgeons will have at their disposal.

Another future treatment opportunity to achieve a near-complete restoration may be biologic cell repair technologies, eg autologous disc chondrocyte transplantation (ADCT) or gene transfer. Combined with a serious attempt at preventive therapy, this strategy could provide a real solution to the serious socioeconomic problem that all industrialized nations face as a result of statistically escalating degenerative spinal disorders. Fusion surgeries will still play a very important role for patients with real instabilities (eg, fractures, tumors) and deformities (eg, scolioses, kyphoses) in the future; fusion, therefore, cannot be completely replaced by arthroplasty.

REFERENCES

1. Deyo RA. Low back pain. *Sci Am*. 1998;279: 28-33.
2. Bertagnoli R. Review of modern treatment options for degenerative disc disease. In: Kaech DL (ed). *Spinal Restabilization Procedures. Diagnostic and Therapeutic Aspects of Intervertebral Fusion Cages, Artificial Discs and Mobile Implants*. Amsterdam: Elsevier; 2002: S.365-S375.
3. Bertagnoli R. Carbon fibre cages. Presented at: 15th Annual Meeting of the American Association of Neurological Surgeons, Section on Disorders of the Spine and Peripheral Nerves, February, 10-13, 1999; New Orleans, LA.
4. Brantigan JW, Steffee AD. A carbon fiber implant to aid interbody lumbar fusion. Two year clinical results in the first 26 patients. *Spine*. 1993;18:2106-2117.
5. Brantigan JW, Steffee AD, Lewis ML, Quinn LM, Persenaire JM. Lumbar interbody fusion using the Brantigan I/F cage for posterior lumbar interbody fusion and the variable pedicle screw placement system: two-years results from an FDA investigational device exemption trial. *Spine*. 2000;25:1437-1444.
6. Kuslich SD, Ulstrom CL, Griffith SL, et al. The Bagby and Kuslich method of lumbar interbody fusion: History, techniques, and two years follow-up results of a United States prospective, multicenter trial. *Spine*. 1998;23:1267-1279.
7. Ray CD. Threaded titanium cages for lumbar interbody fusion. *Spine*. 1997;22:667-680.
8. Bertagnoli R. Ergebnisse der dorsoventralen Stabilisierungsverfahren beim Postnucleotomiesyndrom und bei ausgeprägten osteochondrotischen Veränderungen im Lumbalbereich. In: Matzen KA (ed). *Wirbelsäulenchirurgie II*. Stuttgart, Germany: G. Thieme; 1992:S234-S248.
9. Fritsch E, Heisel J, Rupp R. The failed back surgery syndrome. *Spine*. 1996;21:626-633.
10. Eyre DR, Benya P, Buckwalter J. The intervertebral disc. Part B: Basic sciences perspectives. In: Frymoyer JW, Gordon SL (eds). *New Perspectives on Low Back Pain*. Park Ridge, IL: American Academy of Orthopaedic Surgeons, 1989:147-152.
11. Eysel P, Zoellner J, Rosendahl T, Heine J. *Influence of intradiscal pressure on stiffness of the lumbar disc: 7*. Montpellier: Sauramps Medica; 1998.
12. Götz W, Bertagnoli R, Herken R. Struktur und Zusammensetzung der extrazellulären Matrix normaler menschlicher Nuclei pulposi. *Der Unfallchirurg*. 1999;xx:271.
13. Gower WE, Pedrini V. Age-related variations in protein polysaccharides from human nucleus pulposus, annulus fibrosus, and costal cartilage. *J Bone Joint Surg Am*. 1969;51:1154-1162.
14. Ray CD, Schönmayr R, Kavanagh SA, Assell R. Prosthetic disc nucleus implants. *Riv Neuroradiol*. 1999;12 (s):157-162.
15. Büttner-Janitz K, Schellnack K, Zippel H. Biomechanics of the SB Charité lumbar intervertebral disc endoprosthesis. *IntOrthop (SICOT)*. 1989;13: 173-176.
16. Cinotti G, David T, Postacchini F. Results of disc prosthesis after a minimum follow-up period of two years. *Spine*. 1996;21:995-1000.
17. Marnay T. *Prodisc Prosthesis - 2 Year Follow-up*. Presented at: Annual Meeting of the American Academy of Orthopaedic Surgeons; 1995; Orlando, FL.
18. Marnay T. Lumbar disc replacement - 7-11 years results with ProDisc. Backup. Springer, 2001:9-11.
19. Bertagnoli R. Anterior mini-open approach for Nucleus Prosthesis - a new application technique for PDN. Presented at: 13th Annual Meeting IITS; June 8-10, 2000; St. Williamsburg, VA.
20. Benini A. Indications for single segment intervertebral prosthesis implantation. *Riv Neuroradiol*. 1999;12 (Suppl 1):171-173.
21. Bertagnoli R, Yue J. The treatment of disabling single level lumbar discogenic low back pain with total disc arthroplasty utilizing the Prodisc prosthesis: a prospective study with 2-year minimum follow-up. *Spine J*. In press.
22. Bertagnoli R, Yue J. The treatment of disabling multi-level lumbar discogenic low back pain with total disc arthroplasty utilizing the ProDisc prosthesis: a prospective study with 2-year minimum follow-up. *Spine J*. In press.
23. Aharinejad S, Bertagnoli R, Wicke K, Firbas W, Schneider B. Morphometric analysis of vertebrae and intervertebral discs as a basis of disc replacement. *Am J Anat*. 1990;189:69-76.